

An unusual case of firearm injury: bullet lodged in the tongue

Selçuk Çetin¹, Bülent Eren², Okan Akan², Nursel Türkmen¹, Murat Serdar Gürses¹, Ümit Naci Gündoğmuş³

¹ Uludağ University Medical Faculty, Forensic Medicine Department, Council of Forensic Medicine of Turkey
Bursa Morgue Department, Bursa, Turkey

² Council of Forensic Medicine of Turkey, Bursa Morgue Department, Bursa, Turkey

³ İstanbul University, Forensic Medicine Institute, Council of Forensic Medicine of Turkey, İstanbul, Turkey.

Case was presented in 22nd IALM Congress, İstanbul, 5-8 July 2012.

SUMMARY

Firearm-related injuries are a major problem worldwide, in forensic medicine practice. and unusual presentation of bullet trajectory can create surgical or medico-legal diagnostic problems. A 23-year-old man suffered two gunshot wounds, was taken to emergency department immediately after the incident. Physical examination revealed two entrance gunshot wounds on the left lumbar region under the lower margin of left scapulae and right gluteal region. An exit wound was defined on the lateral side of the right gluteal region which was located 5 cm distance of entrance wound. Radiological investigation showed a bullet in the tongue without any life threatening impairment. A thoracic CT scan and abdominal USG were normal. Following the initial examinations he was hospitalized and the bullet removed from the tongue by a simple surgical operation. An interesting case of gunshot injury where the passage route of bullet extending along from upper posterior part of the left lumbar region to the tongue without vital organ injury or serious disability has been reported.

Keywords: gunshot wound – injury – trajectory – forensic science

Neobvyklý případ střelného poranění: střela zachycená v jazyku

SOUHRN

Zranění způsobená střelnými zbraněmi jsou v soudnělékařské praxi celosvětově jedním z největších problémů. Neobvyklý průběh trajektorie střely může způsobit chirurgovi nebo soudnímu lékaři diagnostické obtíže.

Prezentujeme případ muže stáří 23 let, který byl se dvěma střelnými poraněními přivezen na pohotovost. Vyšetření prokázalo dva vstřely: v levé bederní krajině pod dolním okrajem lopatky a v pravé gluteální krajině. Výstřel byl nalezen na laterální straně gluteální krajiny vpravo ve vzdálenosti 5 cm od vstřelu. Radiologické vyšetření ukázalo přítomnost střely v jazyku, bez život ohrožujícího postižení. CT vyšetření hrudníku a ultrazvuk břicha byly normální. Muž byl hospitalizován a střela z jazyka byla chirurgicky odstraněna. Jde o zajímavý případ střelného poranění s pasáží střely z horní části bederní krajiny do jazyka bez vážnějšího postižení pacienta.

Klíčová slova: střelná rána – zranění – trajektorie – soudní lékařství

Soud Lek 2013; 58(2): 31–32

Firearm-related injuries are a major public and medico legal problem worldwide (1). An unusual presentation of a bullet trajectory can lead to surgical or medico-legal diagnostic problems. The bullet trajectory is one of the parameters which affect the extent of tissue damage in gunshot wounds (1-6). Determination of the missile trajectory may also be useful to clarify any event to judicial authorities, security forces and forensic scientists in determining the ty-

pe and severity of firearm injury and direction of fire We presented a case of interesting gunshot wound.

CASE REPORT

A 23-year-old man suffered two gunshot wounds, was taken to emergency department immediately after the incident. According to his hospital reports, he was cooperative and fully conscious, the vital signs and neurological examination (Glasgow Coma Scale score 15) were normal when he arrived at the hospital. The neck examination was also negative (no thrill, bruit or expanding or pulsatile hematoma). The carotid artery pulses were present and equal bilaterally. Physical examination revealed two entrance gunshot wounds on the left lumbar region under the lower margin of left scapulae and right gluteal region. An exit wound was defined on the lateral side of the right gluteal region which was located 5 cm di-

✉ Correspondence address:

Dr. Bülent Eren

Council of Forensic Medicine of Turkey

Bursa Morgue Department

Osmangazi, Heykel, 16010, Bursa, Turkey.

Tel: +90 224 442 84 00 / 1632; +90 224 222 03 47

Fax: +90 224 442 91 90; +090 224 225 51 70

e-mail: drbulenteren@gmail.com

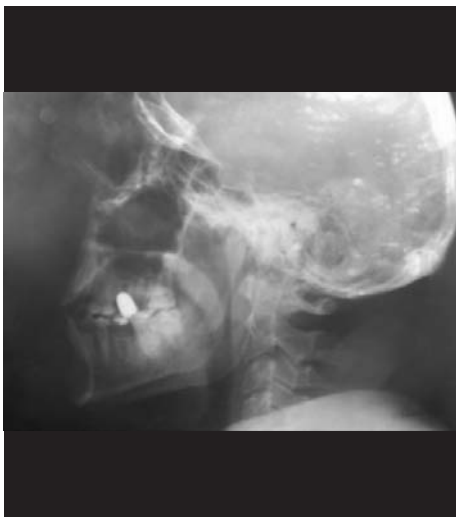

Figure 1. A bullet is seen in the tongue.

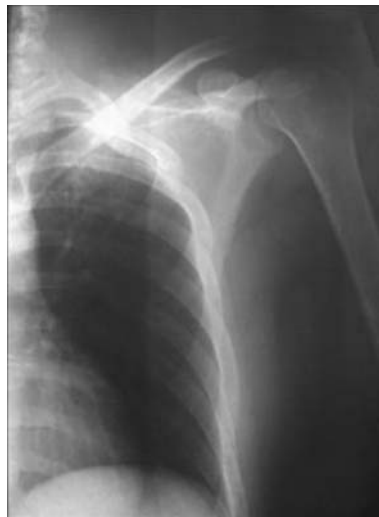

Figure 2. Thoracic X-ray is normal.

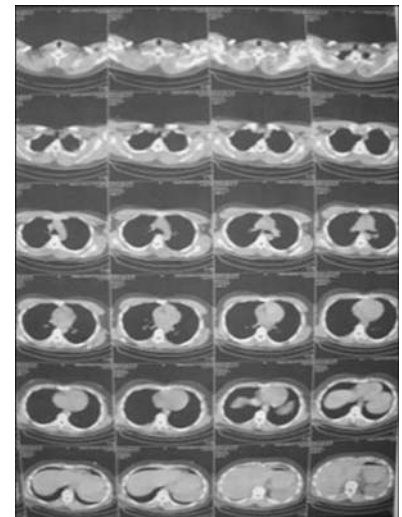


Figure 3. Thoracic CT scan is within normal limits.

stance of entrance wound. Lateral and anterior-posterior cranial X-rays showed a bullet (Figure 1) in the tongue without any life-threatening impairment. A thoracic CT scan, X-ray (Figure 2 and 3) and abdominal USG were normal. Following the initial examinations, he was hospitalized and the bullet removed from the tongue by a simple surgical operation. He was discharged from hospital on the sixth day of surgery. The physical examination, performed 3 months later in the Bursa Branch of the Council of Forensic Medicine of the Ministry of Justice, showed evidence of 3 scars. The scar over the right gluteal region is the result of a bullet entered to body. The other scar, located 5 cm distance laterally, was the result of exit of the bullet. The third scar, under the lower margin of left scapulae, was the result of a bullet that ended up in the tongue.

DISCUSSION

Firearm-related injuries are a major public and medico legal problem worldwide and one of the main issues in forensic medicine practices (1). An unusual presentation of a bullet trajectory can lead to surgical or medico-legal diagnostic problems. The bullet trajectory

is one of the parameters' which affect the extent of tissue damage in gunshot wounds such as distance from which the gun is fired, bullet structure, size, and velocity (1-6). Determination of the missile trajectory may also be of help concerning to clarify any event to judicial authorities, security forces and forensic scientists in determining the type and severity of firearm injury and direction of fire. Despite considerable variability of gunshot injuries, their forensic-medical examination include some basic components such as whether there is any life threatening injury, differential diagnostics of the consequences of multiple injuries attributable to each traumatic factor of the shot, and determining models of the weapons and distance of shot by experimental ballistic investigations (7). Although, the presence of several vital structures throughout the bullet trajectory such as lungs, heart in the thoracic cavity, trachea, esophagus, carotid arteries and veins, cervical part of the thoracic and cervical spinal cord, phrenic nerve and brachial plexus in the neck, there was no vital structure injury in our case. To the best of our knowledge, this is a rare case report in the literature describing a case of a bullet lodged into the tongue after a gunshot injury without any life threatening vital tissue damage although presence of a long bullet trajectory passing near the various important vital structures.

LITERATURA

1. **De Giorgio F, Rainio J.** Two entrances, one exit—an atypical shotgun injury: a case report. *Med Sci Law* 2007; 47(4): 353-356.
2. **Kummoona R, Muna AM.** Evaluation of immediate phase of management of missile injuries affecting maxillofacial region in Iraq. *J Craniofac Surg* 2006; 17(2): 217-223.
3. **Hollerman JJ, Fackler ML, Caldwell DM, Ben-Menachem Y.** Gunshot wounds: 1. Bullets, ballistics, and mechanisms of injury. *AJR Am J Roentgenol* 1990; 155(4): 685-690.
4. **Can M, Yildirim N, Ataç GK.** Dissecting firearm injury to the head and neck with non-linear bullet trajectory: a case report. *Forensic Sci Int* 2010;197(1-3): e13-17.
5. **Godhi S, Mittal GS, Kukreja P.** Gunshot injury in the neck with an atypical bullet trajectory. *J Maxillofac Oral Surg* 2011; 10(1): 80-84.
6. **Chittiboina P, Banerjee AD, Zhang S, Caldito G, Nanda A, Willis BK.** How bullet trajectory affects outcomes of civilian gunshot injury to the spine. *J Clin Neurosci* 2011; 18(12): 1630-1633.
7. **Kolkutin VV, Makarov Ilu, Kutsenko KI.** [Characteristic of injuries inflicted by a blank gunshot]. *Sud Med Ekspert* 2011; 54(3): 28-31.