

TUBULO-SQUAMOUS POLYP OF THE VAGINA

Dundr P.¹, Povýšil C.¹, Mára M.², Kužel D.²

¹Institute of Pathology and ²Department of Obstetrics and Gynecology, 1st Faculty of Medicine and General Teaching Hospital, Charles University in Prague, Czech Republic

Summary

We report a case of an 86-year-old female with a tubulo-squamous polyp of the vagina. Grossly, the polyp measured 2 x 1.5 x 1 cm. Histologically, it was composed of well-circumscribed nests of squamous cells with bland nuclei. Some of the squamous nests showed central spaces filled with necrotic debris. Small tubules were present at the periphery of some of the nests, and there were a few tubules unassociated with the squamous nests. Furthermore, several larger mucinous glands, some with apparent squamous metaplasia, were present. The stroma was fibrous and rather hypocellular. Surface of the polyp was covered by intact squamous epithelium, which was not connected with the underlying lesion. The recently described tubulo-squamous vaginal polyp represents a distinctive entity. To the best of our knowledge, only one study describing a series of ten cases has been reported in the literature to date.

Key words: tubulo-squamous – polyp – vagina

Souhrn

Tubulo-skvamózní polyp vagíny

Popisujeme tubulo-skvamózní polyp vagíny u 86leté ženy. Makroskopicky se jednalo o lézi velikosti 2 x 1,5 x 1 cm. Histologicky byl polyp tvořen dobře ohraničenými hnízdy dlaždicových buněk s blandními jádry lokalizovanými ve fibrózním stromatu. Některá z těchto hnízd měla centrálně dutinu vyplněnou nekrotickým materiálem. V periférii některých hnízd byly přítomny drobné tubuly. Nečetné tubuly byly zastíženy i bez souvislosti s hnízdy dlaždicových epitelii. Kromě toho byly přítomny ojedinělé větší mucinózní žlázy, některé s dlaždicobuněčnou metaplazií. Na povrchu polypu byl intaktní vaginální dlaždicový epitel, který s lézí nesouvisel. Tubulo-skvamózní polyp vagíny je recentně popsána jednotka; v literatuře jsme našli pouze jednu práci popisující 10 případů.

Klíčová slova: tubulo-skvamózní – polyp – vagína

Čes.-slov. Patol., 44, 2008, No. 2, p. 45–47

Vaginal polyps are uncommon and represent a heterogeneous group of lesions. Their histological diagnosis is usually straightforward since most of vaginal polypoid lesions are simple fibroepithelial polyps (1, 10, 11). However, a variety of mesenchymal lesions could present as a polypoid mass, including leiomyoma, superficial myofibroblastoma of the lower female genital tract, rhabdomyoma and embryonal rhabdomyosarcoma (sarcoma botryoides) (4–7, 16). Moreover, some epithelial and mixed tumors may form a polypoid mass. These tumors include enteric-type adenoma, squamous cell and other types of carcinoma, malignant mixed müllerian tumor, and both benign and malignant mixed tumor of the vagina (3, 12, 14, 15). Another type of vaginal polyp has recently been described. It consisted of an admixture of nests of squamous cells and tubules in fibrous stroma. This polyp, which represents a distinctive entity, has been reported in a series of ten cases as the “tubulo-squamous polyp” (9). Herein we report another case of this peculiar lesion together with its immunohistochemical analysis.

CASE REPORT

An 86-year-old female visited her physician because of some vaginal discomfort. She was sent for gynecological

examination. On examination, a polyp was removed from the posterior wall of the upper part of her vagina. Currently, 3 months after the polypectomy, she shows no sign of the disease.

RESULTS

Grossly, the polyp measured 2 x 1.5 x 1 cm. The cross section revealed grayish tissue with unevenly distributed multiple small yellow foci up to 0.2 cm in diameter.

Histologically, the polyp was composed of well-circumscribed nests of squamous cells with bland nuclei (Fig. 1). Mitotic figures were not identified. Some of the squamous nests had central spaces occasionally filled with necrotic debris. Small tubules were present mostly at the periphery of some nests (Fig. 2). In some of these tubules there were PAS and Alcian blue positive mucosubstances, which were located mostly intraluminaly. There were also some small tubules and glands unassociated with the squamous nests, sometimes arranged into small clusters. These tubules were lined by a single layer of cuboidal cells with small bland nuclei and scarce cytoplasm. In some tubules unassociated with squamous elements there was apparent a double layer of basal and luminal cells. In some of these tubules, there was

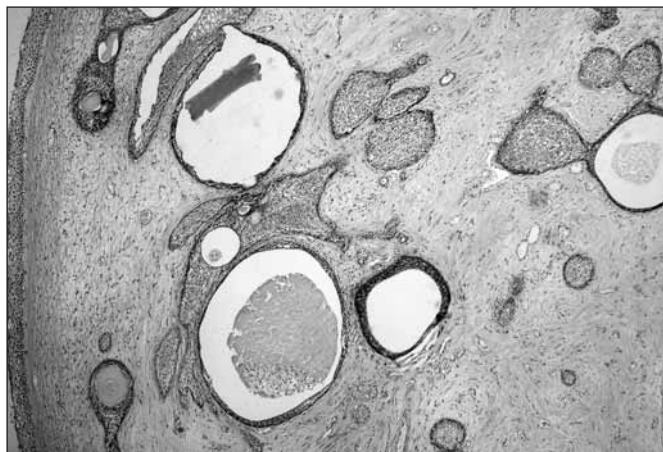


Fig. 1. Low power view showing nests of squamous cells with some central spaces. Note intact surface squamous epithelium on the left side (H&E, 40)

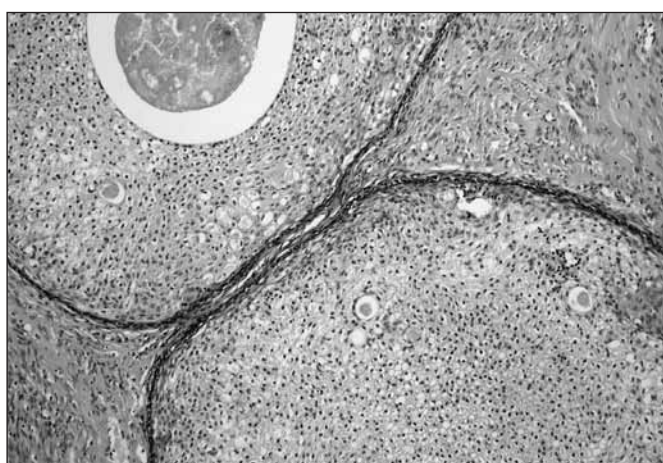


Fig. 2. Nests of squamous cells with small tubules. Note the intraluminal secretion in some tubules (H&E, 200)

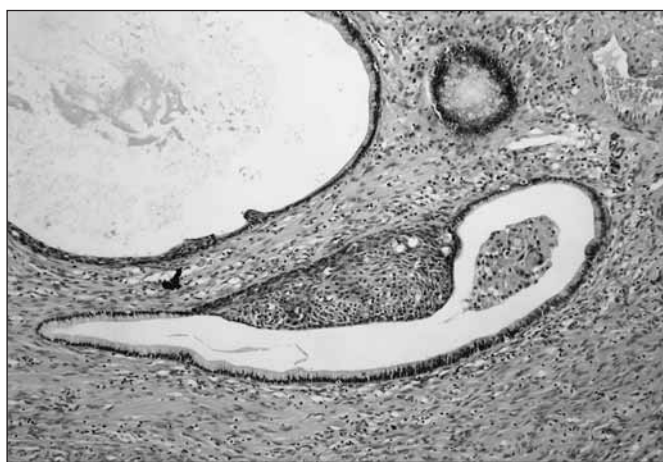

Fig. 3. Large mucinous glands with focal squamous metaplasia (H&E, 200)

intraluminal eosinophilic, homogeneous, PAS-positive, and Alcian blue negative secretion. However, the cytoplasm of these cells contained no PAS or Alcian blue positive substances. Furthermore, a few larger mucinous glands, some of them with apparent squamous metaplasia, were present (Fig. 3). A single layer of columnar cells with ample clear cytoplasm lined these glands. The cytoplasm of these cells was Alcian blue and PAS positive. The stroma was dense,

fibrous and mostly hypocellular. On the surface of the polyp, there was intact squamous epithelium unconnected with the underlying lesion.

Immunohistochemically, both the squamous and glandular/tubular elements showed positivity with cytokeratins AE1/AE3 and 34 β E12. Cytokeratin 7 was positive in glandular and tubular cells, whereas squamous cells were negative. Cytokeratin 20 was entirely negative. CD10 showed luminal positivity in some tubules and in squamous nests confined to the basal cell layer. CA125 was positive only in mucinous glands, the tubules and the squamous cells were negative. The squamous elements exhibited almost diffuse nuclear positivity with the estrogen receptors, and they were negative with the progesterone ones. Both the estrogen and the progesterone receptors were negative in tubular and glandular cells. CD56, prostate specific antigen (PSA), and prostatic acidic phosphatase (PSAP) were negative. The stromal cells showed positivity with vimentin, estrogen and progesterone receptors. Some of the stromal cells were α -actin positive. Other markers examined were negative in the stromal cells, including all cytokeratins. Proliferative activity (Ki-67 index) was low with only occasional positive nuclei.

DISCUSSION

Vaginal polyps are uncommon lesions. Most of them are fibroepithelial (stromal) polyps whose histological diagnosis is usually straightforward (1, 10, 11). Variety of other mesenchymal, epithelial, or mixed lesions may present as a polypoid mass. These lesions include leiomyoma, superficial myofibroblastoma of the lower female genital tract, rhabdomyoma, embryonal rhabdomyosarcoma (sarcoma botryoides), enteric-type adenoma, squamous cell- and other types of carcinoma, malignant mixed müllerian tumor, and both benign and malignant mixed tumor of the vagina (3–7, 12, 15, 16). Furthermore, there are a few cases describing the benign Brenner tumor of vagina forming polypoid mass (2, 13). Recently, a new entity – a tubulo-squamous polyp of the vagina was described in a series of ten cases (9). This lesion represents a distinctive entity characterized by an admixture of epithelial and stromal components. The epithelial component consists of well-demarcated nests of cells which are predominantly squamous in type with a minor component of tubules. There are some central lumina within these nests of squamous cells filled with keratin debris. Some of the squamous nests contain small tubules located predominantly at the periphery. These tubules are lined by cuboidal cells with scarce clear or eosinophilic cytoplasm. In three of the reported cases, several tubules unassociated with squamous elements were found. In two of the latter, a double layer of cells was present with a flattened basal cell layer and cuboidal luminal cells. In all but one case, there was no connection with the surface squamous epithelium. In our case, the overall histological finding was similar, with an exception of the presence of larger glandular spaces lined by a single layer of cylindrical mucinous cells with ample clear cytoplasm. However, these spaces were rare and some of them showed extensive squamous metaplasia. The stromal component of the reported cases was fibrous and rather hypocellular (9). However, in our case, there was an admixture of stromal myofibroblastic cells. In our case and one of the reported cases, the edge of the lesion appeared to be well circumscribed. However, in all the other cases, the lesions merged imperceptibly into the surrounding connective tissue and extended to the base of surgical specimens.

There are several theories regarding the histogenesis of the tubulo-squamous vaginal polyp. The Müllerian and Wolffian origin as well as the origin from the urogenital sinus or from vaginal adenosis was hypothesized (9). However, the authors

suppose that these possibilities are unlikely. Other possible theories include the derivation from mesonephric remnants or misplaced Skene glands, which are the female equivalent of prostatic tissue (8,9). This theory is supported by the fact that some of the reported cases showed PSA and PSAP positivity. In our case, structures resembling both the mesonephric remnants and ectopic Skene gland were found; however, PSA as well as PSAP were negative.

The differential diagnosis of tubulo-squamous polyp include mainly the benign mixed tumor of the vagina (spindle cell epithelioma) (3,12,15). This tumor is composed of an admixture of epithelial and stromal elements. The epithelial component consists of nests of benign-appearing squamous cells, and, less frequently, glands. However, the stromal component predominates and consists of numerous spindle cells without atypias, which are usually strongly immunoreactive for cytokeratins. Moreover, the benign mixed tumor of the vagina is usually well circumscribed and occurs in young to middle-aged women with predilection for hymenal region. In contrast, the tubulo-squamous polyp shows predominance of epithelial cells and the stroma is usually hypocellular. In the reported cases as well as in our case the stromal component was cytokeratin negative. Moreover, the lesions are usually non-circumscribed and occur in older female in the upper part of the vagina. Another differential diagnosis includes the vaginal Brenner tumor, which has been reported in a few cases (2,13). Based on the morphology of these cases, it was suggested that at least some of them could represent lesions similar to the tubulo-squamous polyp with transitional rather than squamous morphology (9). Yet another hypothetical differential diagnosis could include squamous cell carcinoma. However, the squamous carcinoma lacks the characteristic tubules. Moreover, the nuclear atypias and mitotic figures are absent in tubulo-squamous polyps.

In conclusion, we described another case of the tubulo-squamous polyp of the vagina representing a recently described distinctive entity. This lesion should be considered in the differential diagnosis of other lesions that could form vaginal polyps, especially the benign mixed tumor of the vagina.

REFERENCES

1. **Al-Nafussi, A.I., Rebello, G., Hughes, D., et al.:** Benign vaginal polyp: a histological, histochemical and immunohistochemical study of 20 polyps with comparison to normal vaginal subepithelial layer. *Histopathology* 1992, 20: 145-150
2. **Ben-Izhak, O., Munichor, M., Malkin, L., et al.:** Brenner tumor of the vagina. *Int. J. Gynecol. Pathol.* 1998, 17: 79-82
3. **Branton, P.A., Tavassoli, F.A.:** Spindle cell epithelioma, the so-called mixed tumor of the vagina: a clinicopathological, immunohistochemical and ultrastructural analysis of 28 cases. *Am. J. Surg. Pathol.* 1993, 17: 509-515
4. **Ganesan, R., McCluggage, W.G., Hirschowitz, L., et al.:** Superficial myofibroblastoma of the lower female genital tract: report of a series including tumours with a vulval location. *Histopathology* 2005, 46: 137-143
5. **Iversen, U.M.:** Two cases of benign vaginal rhabdomyoma. *Case reports. APMIS* 1996, 104: 575-578
6. **Laskin, W.B., Fetsch, J.F., Tavassoli, F.A.:** Superficial cervicovaginal myofibroblastoma: fourteen cases of a distinctive mesenchymal tumor arising from the specialised subepithelial stroma of the lower female genital tract. *Hum. Pathol.* 2001, 32: 715-725
7. **McCluggage, W.G.:** A review and update of morphologically bland vulvovaginal mesenchymal lesions. *Int. J. Gynecol. Pathol.* 2005, 24: 26-38
8. **McCluggage, W.G., Ganesan, R., Hirschowitz, L., et al.:** Ectopic prostatic tissue in the uterine cervix and vagina. Report of a series with a detailed immunohistochemical analysis. *Am. J. Surg. Pathol.* 2006, 30: 209-215
9. **McCluggage, W.G., Young, R.H.:** Tubulo-squamous polyp. A report of ten cases of a distinctive hitherto uncharacterized vaginal polyp. *Am. J. Surg. Pathol.* 2007, 31: 1013-1019
10. **Nucci, M.R., Fletcher, C.D.:** Vulvovaginal soft tissue tumours: update and review. *Histopathology* 2000, 36: 97-108
11. **Nucci, M.R., Young, R.H., Fletcher, C.D.M.:** Cellular pseudosarcomatous fibroepithelial stromal polyps of the lower female genital tract: an underrecognized lesion often misdiagnosed as sarcoma. *Am. J. Surg. Pathol.* 2000, 24: 231-240
12. **Oliva, E., Gonzales, L., Dionigi, A., et al.:** Mixed tumor of the vagina: an immunohistochemical study of 13 cases with emphasis on the cell of origin and potential aid in differential diagnosis. *Mod. Pathol.* 2004, 17: 1243-1250
13. **Rashid, A.M., Fox, H.:** Brenner tumor of the vagina. *J. Clin. Pathol.* 1995, 48: 678-679
14. **Sebenik, M., Yan, Z., Khalbuss, W.E., et al.:** Malignant mixed müllerian tumor of the vagina: case report with review of the literature, immunohistochemical study, and evaluation for human papilloma virus. *Hum. Pathol.* 2007, 38: 1282-1288
15. **Sirota, R.L., Dickersin, G.R., Scully, R.E.:** Mixed tumor of the vagina. A clinicopathological analysis of eight cases. *Am. J. Surg. Pathol.* 1981, 5: 413-422
16. **Stewart, C.J., Amanuel, B., Brennan, B.A. et al.:** Superficial cervico-vaginal myofibroblastoma: a report of five cases. *Pathology* 2005, 37: 144-148

*MUDr. Pavel Dundr, Institute of Pathology,
1st Faculty of Medicine and General Teaching Hospital,
Charles University, Studničkova 2, Prague 2,
12800, Czech Republic
Phone: +420224968624
Email: pdundr@seznam.cz*