
Desmin-Positive and alpha-Smooth Muscle Actin Positive Chondrocytes in Human Defective Articular Cartilage-Preliminary Report

¹Povýšil C., ¹Dundr, P., ¹Tvrđík D., ²Podškubka A., ³Kaňa R., ⁴Horák M.

¹Ústav patologie 1. LF UK a VFN a Katedra patologické anatomie IPVZ, Praha

²Ortopedická klinika 1. LF UK a FNB a IPVZ, Praha

³Oddělení ORL VFN, Praha

⁴Radiodiagnostická klinika 1. LF UK a FNB, Praha

Summary

We studied the results of immunostaining for S-100 protein, alpha-smooth muscle actin, muscle specific actin and desmin in articular cartilage specimens obtained during an arthroscopy from eight patients with different degrees of osteoarthritis of the knee joint. In all cases, most of the cartilage cells were strongly positive for S-100 protein. Actin positive chondrocytes were present in four samples showing repair cartilage changes with occurrence of fibrocartilage tissue. Moreover, in one case, we observed typical desmin-positive chondrocytes in the layer of cartilage filling the defect of the articular cartilage surface. The expression of desmin can be regarded as a reaction to trauma or the indication of an inherent abnormality. The chondrocytes probably switched on smooth muscle features during the healing process, because desmin is to a great extent a typical muscle cell marker. This fact could probably support our previous supposition that cartilage cells expressing muscle markers could be designated as myochondroblasts and myochondrocytes analogously to the terminology of myofibroblasts. It is possible that during the healing of the cartilage defects, such a transformation of the immunophenotype of the cartilage cells is quite frequent, but it could also be only transient nature only

Key words: articular cartilage – osteochondritis – actin-positive chondrocytes – desmin positive chondrocytes – myochondrocytes

Souhrn

Dezmin-pozitivní a alfa-aktin pozitivní chondrocyty v defektech lidské kloubní chrupavky

Autoři studovali expresi S-100 proteinu, aktinu hladké svaloviny, svalového aktinu a dezminu v kloubních chrupavkách odebraných při artroskopickém vyšetření u 8 pacientů s různým stupněm osteoartritidy kolenního kloubu. Ve všech případech byly buňky chrupavčité tkáně zřetelně pozitivní v reakci k průkazu S-100 proteinu. Aktin pozitivní chondrocyty byly zaznamenány ve 4 vzorcích s reparativními změnami při osteoartritidě provázenými tvorbou fibrózní chrupavčité tkáně. Navíc u jednoho z těchto vzorků byly současně pozorovány dezmin pozitivní chondrocyty ve vrstvě chrupavčité tkáně vyplňující povrchový defekt v kloubní chrupavce. Expresi dezminu je možno chápat jako důsledek reakce na trauma nebo výraz vrozené abnormality. Chondrocyty pravděpodobně získaly během hojivého procesu některé rysy buněk hladké svaloviny, neboť dezmin je do značné míry marker svalových buněk. Tento fakt by mohl podporovat původní předpoklad autorů, že chondrocyty exprimující svalové markery by mohly být označovány v analogii s myofibroblasty jako myochondrocyty a myochondroblasty. Je pravděpodobné, že takováto transformace imunofenotypu chondrocytů je v průběhu hojení defektů chrupavky dosti častá, i když možná pouze přechodného charakteru.

Klíčová slova: kloubní chrupavka – osteoartritis – aktin pozitivní chondrocyty – dezmin pozitivní chondrocyty- myochondrocyty

Čes.-slov. Patol., 41, 2005, No. 4, p. 133–136

Relatively little is known about the cytoskeleton of the human articular chondrocytes. Some of the present authors (6) reported on the occurrence of muscle specific actin and alpha-

smooth muscle actin in some S-100 protein positive chondrocytes and chondroblasts of the bone chondroblastoma and exceptionally also in chondrosarcomas for the first time several years

ago. This finding prompted us to suggest that such cells might be referred to as myochondroblasts and myochondrocytes. Further research confirmed our results and demonstrated the presence of alpha-smooth muscle actin in cells of chondrocytic appearance in a canine meniscus (4) and intervertebral discus (7) and also in human articular cartilage with osteoarthritic changes (2) and in chondromyxoid fibroma (5). Articular chondrocytes may perhaps utilize the contractile actin isoform in manipulating the extracellular matrix of articular cartilage (2).

It is well known that a cytoskeleton is not only composed of microfilaments of the actin type, but also contains other components represented by microtubules and intermediate filaments. The group of intermediate filament proteins is represented by keratins, vimentin, desmin, neurofilaments protein, glial fibrillary acidic protein and the lamins. Till now, only vimentin has been proved in cartilaginous chondrocytes and so we were very surprised when we observed the distinct positivity of desmin in the chondrocytes of the articular cartilage tissue removed before implantation of cartilage cells culture tissue from a patient with an articular cartilage defect. We present here our preliminary findings on the occurrence of a positive desmin and alpha-smooth muscle actin immunostaining of chondrocytes from defective articular cartilage.

Material and Methods

Eight representative bioptic samples of articular cartilage obtained during an arthroscopic examination of patients with osteoarthritis of different degree were chosen for the purpose of our study. A histological examination and immunohistochemical staining were performed on formalin-fixed paraffin-embedded tissue. For the purpose of our immunohistochemical studies we used the avidin-biotin complex (ABC) technique. Primary monoclonal mouse antibodies against S-100 protein (1:200, DAKO), alpha-smooth muscle actin (1:100, Sigma), muscle actin (1:100, DAKO) and desmin (1: 200, DAKO) were applied. Negative controls were performed by substituting the primary antibody with non-immune mouse serum.

Isolation of total RNA, synthesis of cDNA and RT-PCR analysis were performed by standard procedure described in our previous work (8). The detection of the putative desmin transcript was carried out with the following primers:

5'-TCAGCTTCAGGAACAGCAGG-3' (sense primer),

5'-GGTGTCGGTATTCCATCATC-3' (anti-sense primer).

PCR conditions were : 95 °C for 3 minutes, annealing at 57 °C for 1 minute, and extension at 72 °C for 1 minute, followed by 45 cycles with the programs of denaturation at 95 °C for 1 minute, annealing at 57 °C for 1 minute, and extension at 72 °C for 1 minute. The reaction was accomplished with a final extension at 72 °C for 10 minutes.




Fig. 1. Biopsy specimen from the region of the repaired articular cartilage defect. Subchondral bone is covered by a cartilage layer composed of hyaline cartilage and fibrocartilage with randomly oriented bundles of collagen fibres. HE, x 80

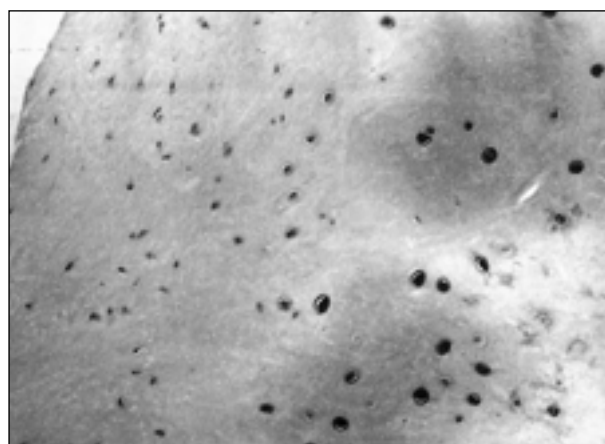


Fig. 2. Desmin positive chondrocytes in the same region as demonstrated in Fig. 1.

Results

The histological appearance of the specimens of human articular cartilage evaluated in this study varied from almost normal (4 cases) to samples displaying mild osteoarthritic changes represented by the presence of small defects solely contained in the layer of articular cartilage (4 cases). In the region of these defects the subchondral bone was covered by a layer of

non-vascular cartilage showing a mixture of hyaline cartilage and fibrocartilage. In the superficial part there were flattened disc-like chondrocytes and densely packed, horizontally arranged collagen fibrils. On the contrary, the deep major part of the cartilage layer was composed of chondrocytes occupying well-defined lacunae and abundant intercellular matrix containing numerous proteoglycans and some thick, irregularly oriented bundles of collagen. Pure hyaline cartilage matrix was present only in the neighbourhood of the chondrocytes. An underlying calcification zone of the cartilage was present in the typical site and formed the deepest component of the cartilage layer. The subchondral bone plate was wholly preserved.

In all cases of both groups we observed distinct immunostaining of the majority of chondrocytes in different layers of the articular cartilage with specific antibody against S-100 protein. Alpha-smooth actin and muscle actin positive chondrocytes occurred only in the samples with osteoarthritic changes represented by the presence of small defects filled with hyaline cartilage and fibrocartilage. They were irregularly distributed in whole thickness of the cartilage layer. Desmin-positive chondrocytes were observed in only one specimen, where they lay above the calcified zone of the cartilage. They had the typical features of the lacunar cells of the hyaline cartilage and were embedded in homogenous extracellular matrix containing proteoglycans. No vessels or reparative changes were observed.

An RT-PCR analysis detected a putative desmin transcript in the same specimen with desmin-positive chondrocytes and confirmed the results of our immunohistochemical examinations.

Discussion

The findings of this study revealed that human articular cartilage has some potential for spontaneous regeneration. Cartilage tissue obtained from the surface articular defects comprised mixture of hyaline cartilage and fibrocartilage. Many chondrocytic cells contained alpha-smooth muscle actin and muscle actin and so we can confirm the findings of Wang et al. (9), who observed similar actin containing chondrocytes during healing of surgically created defects in adult canine articular cartilage. It is supposed that contractile cells may be contributing to the wound healing of the defects of articular cartilage.

The present study is the first report showing

the presence of desmin in chondrocytes from human articular cartilage. The desmin-positive cells had a typical chondrocyte appearance and simultaneously expressed S-100 protein, alpha-smooth actin, and muscle actin. These desmin-positive chondrocytes were surrounded by a typical intercellular matrix of hyaline cartilage. This indicated that the desmin-positive cells were not derived from other tissue sources. The maximum of desmin positive cells was situated above the calcified layer of the articular cartilage and the bone lying below the articular cartilage did not show any pathological changes. No proliferation of vessels was observed and there were no signs of inflammation. Our immunohistochemical findings were verified by means of the RT-PCR technique in the same sample and the results of this molecular method confirmed the immunohistochemical findings. We think that the desmin-positive cells do not correspond to myofibroblasts because these cells coexpress S-100 protein, a fact that we verified by means of the double-labelling immunohistochemical technique in the same preparation.

Desmin is a cytoplasmic, intermediate filament protein characteristically found in muscle cells and myofibroblasts and in the neoplasms associated with them. In smooth muscle cells it appears with dense cytoplasmic bodies and dense subplasmalemmal plaques. In striated muscle desmin filaments are linked to sarcomeric Z disks. Desmin may also be coexpressed by giant cell tumours of the tendon sheath, angiomatoid fibrous histiocytoma, neuroblastoma, mesothelioma and neoplasms with so-called divergent phenotypes such as PNETs, epithelioid sarcomas, malignant rhabdoid tumours and MPNSTs. Moreover, desmin is also expressed by the fibroblastic reticulum cells of the lymph node, the submesothelial fibroblasts, and the endometrial stromal cells. Therefore it is clear that desmin is not specific purely for muscle cells and muscle tumours.

It is difficult to explain the desmin positivity of chondrocytes. The expression of the desmin can be regarded as a reaction to trauma, or the expression of an inherited abnormality. These cells probably have the ability to switch on smooth-muscle features and the presence of desmin and actin can thus be interpreted simply as smooth muscle metaplasia, or as a trans-differentiation towards smooth muscle. In view of our present knowledge of the common presence of actin in chondrocytes from repair cartilage such a possibility is not surprising, because smooth-muscle cells also express actin and desmin simultaneously. We found desmin-positive cartilage cells in cartilage tissue from the defect fully contained in articular cartilage. Minor defects fully contained in articular cartilage may persist

with no sign of healing, or heal with limited filling with fibrous tissue, fibrocartilage, or hyaline cartilage(3). In contrast, full-thickness articular cartilage defects that penetrate the subchondral bone more regularly show filling of the defect with reparative tissue due to the introduction of reparative cells from blood vessels and bone marrow. In our case the defect was partly filled with hyaline cartilage chondrocytes with an admixture of fibrocartilage with randomly oriented bundles of collagen fibres. The presence of the fibrocartilage tissue indicates that a partial healing process occurred at this site and therefore the cartilage defect was partly eliminated. It is possible that during this healing process such a transformation of the immunophenotype of cartilage cells is quite frequent, but we do not know if the desmin expression is transient or permanent. Therefore further studies of the tissue obtained from articular cartilage defects are needed.

In conclusion, our results indicate that during the healing of the cartilage defect not only alpha-smooth muscle actin but also desmin could be expressed by some typical chondrocytes. The expression of desmin can be regarded as a reaction to trauma or the indication of an inherent abnormality. The chondrocytes probably switched on smooth-muscle features, because desmin is a rather typical muscle cell marker. On the basis of this finding we suppose that chondrocyte phenotype is plastic and can be modulated by microenvironmental stimuli. This fact could probably support our previous supposition that chondrocytes showing positivity of the muscle markers could be designated as myochondrocytes and myochondroblasts analogously to the terminology of myofibroblasts.

**Práce vznikla s podporou GA MZ ČR
č. NR/8150-4
ND/7375-3**

References

1. **Bernard, M. A., Hogue, D.A., Cole, W. G. et al.:** Cytoskeletal abnormalities in chondrocytes with EXT1 and EXT2 mutations. *J. Bone Miner. Res.* 15, 200, s. 442–450. – 2. **Kim, A.C., Spector, M.:** Distribution of chondrocytes containing alpha-smooth muscle actin in human articular cartilage. *J. Orthop. Res.*, 18, 200, s. 749 – 755. – 3. **Mainil-Varlet, P., Aigner, T., Brittberg, M. et al.:** Histological assessment of cartilage repair. *J. Bone Joint Surg.* 85 A, 2003, Suppl. 2, s. 45–57. – 4. **Mueller, S. M., Schneider T. O., Shortkroff, S. et al.:** Alpha-smooth actin and contractile behaviour of bovine meniscus cells in type I and type II collagen-GAG matrices. *J. Biomed. Mater. Res.*, 45, 1999, s. 157-166. – 5. **Nielsen, G. P., Keel, S.B., Dickersin, G. R. et al.:** Chondromyxoid fibroma: A tumour showing myofibroblastic, myochondroblastic, and chondrocytic differentiation. *Mod. Pathol.*, 12, 1999, s. 514-517. – 6. **Povýšil, C., Tomanová, R., Matějovský, Z.:** Muscle-specific actin expression in chondroblastoma. *Hum. Pathol.*, 28, 1997, s. 316–320. – 7. **Schneider, T. O., Mueller, S. M., Shortkroff, S.:** Expression of alpha-smooth muscle actin in canine intervertebral disc cells in situ and in collagen-glycosaminoglycan matrices in vitro. *J. Orthop. Res.*, 17, 1999, s. 192–199. – 8. **Tvrđík, D., Povýšil, C., Dundr. P. et al.:** Molecular diagnosis of synovial sarcoma: detection of SYT-SSX1/2 fusion transcript by RT-PCR in paraffin-embedded tissue. *Med. Sci. Monit.*, 11, 2005, s. 1–7. – 9. **Wang, Q., Breinan, H. A., Hsu H., Spector M.:** Healing of defects in canine articular cartilage: distribution of non-vascular alpha-smooth muscle actin-containing cells. *Wound Rep. Reg.* 8, 2000, s. 245-258

*Prof. MUDr. C. Povýšil, DrSc.
Ústav patologie 1. LF UK
Studničkova 2, 120 00 Praha 2
Telefon: 224968660
Fax: 224911715*

Wrightův zákon:

Lékař může ještě svůj omyl nějak zakamuflovat, architekt však může zákazníkovi pouze poradit, aby začal pěstovat vinnou révu.

Thomsův zákon šťastného manželství:

Délka manželství je nepřímo úměrná nákladům na veselku.

Pravidlo manželského lože:

Vždycky usne dřív ten, který chrápe.

Colvardova logická premisa:

Každá pravděpodobnost je padesátiprocentní. Buď to vyjde, nebo ne.

Colvardův netaktní komentář:

Což platí zejména, máme-li co dělat se ženami.

Grelbův komentář ke Colvardově premise:

Tendence však je taková, že vám to z 90 procent nevyjde.